

PATIENT

Sally Pfeffer

SPECIES

Canine

BREED

Terrier Mix

SEX

FS

AGE

3 years

WEIGHT

9 kg

INTERPRETED BY

Remo Lobetti, BVSc,
MMedVet (Med),
PhD, Dipl. ECVIM

**IMAGING
PERFORMED BY**

Sonya Myers, DVM

HOSPITAL NAME

Treasure Coast
Animal Emergency

REFERRING VET

Dr Cail

INVOICE

302607

DATE

10/22/21

PRESENTING CLINICAL SIGNS

History: Hemorrhagic diarrhea.

Physical Examination: N/A.

Urinalysis: N/A.

CBC: N/A.

Serum Biochemistry: N/A.

Radiographic Findings: N/A.

ULTRASONOGRAPHIC EXAMINATION OF THE ABDOMEN

Urinary System

Full urinary bladder with a normal appearance and thickness of the wall. Normal anechoic urine with no sediment or uroliths evident.

Normal trigone area, proximal urethra (0.26 cm) and iliac blood vessels.

Normal iliac lymph nodes. Ureters not visualized.

Normal renal size (left 4.3 cm, right 4.6 cm), echogenic appearance, cortico-medullary differentiation, capsule, and pelvis.

Reproductive System

N/A.

Adrenal Glands

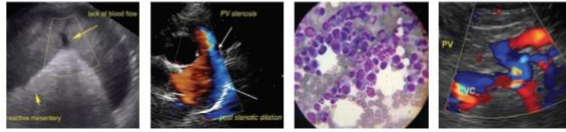
Normal shape, echogenic appearance, size, and position. Left 0.47/0.42 cm, right 0.6/0.48 cm.

Spleen

Normal size and echogenic appearance. Smooth homogenous parenchyma, smooth curvilinear capsule, and normal vasculature. No evidence of inflammatory, neoplastic, infarction, or infiltrative changes noted.

Liver

Normal size, echogenic appearance, and portal markings. No nodules or masses evident. Full gall bladder containing normal anechoic bile. Normal thickness and echogenic appearance of the gall bladder wall. Normal bile duct (0.14 cm).



PATIENT

Sally Pfeffer

SPECIES

Canine

BREED

Terrier Mix

SEX

FS

AGE

3 years

WEIGHT

9 kg

INTERPRETED BY

Remo Lobetti, BVSc,
MMedVet (Med),
PhD, Dipl. ECVIM

**IMAGING
PERFORMED BY**

Sonya Myers, DVM

HOSPITAL NAME

Treasure Coast
Animal Emergency

REFERRING VET

Dr Cail

INVOICE

302607

DATE

10/22/21

Gastrointestinal

Normal appearance of the gastro-esophageal junction, duodenum, small intestine, ileo-cecal junction, and colon with no loss of layering, normal wall thickness (stomach 0.45 cm, duodenum 0.32 cm, jejunum 0.26 cm) and peristalsis, and no distension of the lumen.

Pancreas

Normal size (right 0.9 cm) and echogenic appearance. Regular capsule. Normal echogenic appearance of the mesentery and fat surrounding the pancreas.

Free Abdomen

No mesenteric lymphadenomegaly.
No ascites.

ULTRASONOGRAPHIC FINDINGS

Primary findings:

- None

Secondary findings:

- None.

INTERPRETATION OF THE FINDINGS & FURTHER RECOMMENDATIONS

Normal ultrasound examination of the abdomen.

The information and recommendations provided are based on the images presented by the referring veterinarian. No evaluation can be communicated regarding pathology that was not visible in the image/video clips provided.

Thank you for this referral. If the clinical or image interpretation does not parallel your findings or if I can be of any further assistance please contact me.

Remo Lobetti, BVSc, MMedVet (Med), PhD, Dipl. ECVIM (Internal Medicine)
rlobetti@mweb.co.za